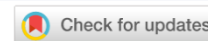

ANIMAL PATHOLOGY, MORPHOLOGY, PHYSIOLOGY,  
PHARMACOLOGY AND TOXICOLOGY  
ПАТОЛОГИЯ ЖИВОТНЫХ, МОРФОЛОГИЯ, ФИЗИОЛОГИЯ,  
ФАРМАКОЛОГИЯ И ТОКСИКОЛОГИЯ



UDC: 599.323.5;575.854;615.099

Original Empirical Research

<https://doi.org/10.23947/2949-4826-2025-24-4-43-54>


EDN: KCVVUX

**A Study on Morphofunctional State of Djungarian Hamster (*Phodopus Sungorus*) Lungs and Main Organs of Detoxification under Long-Term Exposure to E-Cigarette Aerosol**

Andrey V. Sakharov<sup>1</sup> , Vitalina I. Byrdina<sup>1</sup> , Pavel A. Zadubrovsky<sup>1,2</sup> ,

Inna V. Zadubrovskaya<sup>1,2</sup> , Olga F. Potapova<sup>2</sup> , Ekaterina Yu. Kondratyuk<sup>3</sup> , Sergey S. Bondarenko<sup>4</sup>,

Evgeny A. Novikov<sup>2,5</sup>

<sup>1</sup>Novosibirsk State Pedagogical University, Novosibirsk, Russian Federation

<sup>2</sup>Institute of Systematics and Ecology of Animals, Siberian Branch of Russian Academy of Sciences, Novosibirsk, Russian Federation

<sup>3</sup>Research Institute of Clinical and Experimental Lymphology – Branch of Institute of Cytology and Genetics, Siberian Branch of Russian Academy of Sciences, Novosibirsk, Russian Federation

<sup>4</sup>Saint Petersburg State Institute of Technology, Saint Petersburg, Russian Federation

<sup>5</sup>Novosibirsk State Agrarian University, Novosibirsk, Russian Federation

[inna\\_zadubrovskaya@mail.ru](mailto:inna_zadubrovskaya@mail.ru)

### Abstract

**Introduction.** The liquids of electronic nicotine delivery systems (ENDS), which have the multi-component composition, represent a major environmental hazard, as they contain extremely toxic substances. Although the popularity of this form of smoking grows, the data on the biological effects of long-term exposure of animals and humans to e-cigarette and vape components are insufficient. The aim of the present study is to investigate the morphofunctional state of the lungs and main organs of detoxification in Djungarian hamsters under long-term exposure to ENDS aerosol.

**Materials and Methods.** The research was conducted in 2021 in the colony of laboratory Djungarian hamsters kept at the Institute of Systematics and Ecology of Animals SA RAS. Thirty-six hamsters were divided into two groups. During 80 days, animals in the experimental group (10 females and 10 males) were exposed to vapour from heating the X-3 Yoghurt Pear liquid. The procedure was performed twice a day for 10 minutes, with a 2-hour interval. Hamsters in the control group (8 males and 8 females) were placed in exposure chambers but were not exposed to vapour. At the end of the 80-day experiment, the animals were decapitated, and organs were collected for preparing thin histological sections. The specimens were stained with Boehmer's hematoxylin and eosin. Collagen distribution was determined using the Mallory method. Histological specimens of organs were examined under transmission light microscope

**Results.** In experimental animals exposed to toxic vapour, a homogeneous black substance was detected in bronchial epithelial cells and in the alveolar interstitium. In the lung parenchyma, signs of developing interstitial pneumonia, atelectasis, emphysema, and obstructive bronchitis were detected, indicating impaired ventilation-perfusion relationships in the lung tissue and gas exchange disorder. In the kidneys, the homogeneous substance was localized in the lumen of renal tubules. Light optical microscopy revealed the main signs of lethal damage in renal epithelial cells. Strongly expressed dilation of the renal glomerular capillaries, coupled with a nearly 2-fold reduction in the surface area of renal corpuscles compared to control samples, indicates impaired hemodynamics and disrupted renal reabsorption-filtration function. Regarding the liver, a high level of localization of evolutionarily adapted to detoxification dark hepatocytes dying by apoptosis in the centrilobular region of the lobule, indicates the involvement of toxic substances in this process, which enter the liver with the blood.

**Discussion and Conclusion.** The experiment demonstrated the general pathogenic effects of ENDS aerosol on the lungs and organs of detoxification in animals after long-term exposure to it. Such studies are necessary in the context of the observed growth of consumption of the nicotine delivery systems at the global market.

**Keywords:** electronic nicotine delivery systems, ENDS, e-cigarette aerosol, vapes, Djungarian hamsters, long-term exposure, morphofunctional changes, lungs and organs of detoxification, renal failure, hepatocyte apoptosis

**Declaration on Compliance with the Principles of the European Convention for the Protection of Vertebrate Animals Used for Experimental and Other Scientific Purposes:** the authors declare that all research was conducted in compliance with the principles of Good Laboratory Practice.









**Acknowledgements.** We would like to express our gratitude to the students of Novosibirsk State Pedagogical University: Daria Tokareva, Daria Tolstova, and Ekaterina Zezyulina for their assistance in preparing the article.

**Funding.** The work was carried out in the frame of the Federal Program for Fundamental Scientific Research for 2021–2025 FWGS-2021-0003.

**For Citation.** Sakharov AV, Byrdina VI, Zadubrovsky PA, Zadubrovskaya IV, Potapova OF, Kondratyuk EYu, Bondarenko SS, Novikov EA. A Study on Morphofunctional State of Djungarian Hamster (*Phodopus Sungorus*) Lungs and Main Organs of Detoxification under Long-Term Exposure to E-Cigarette Aerosol. *Russian Journal of Veterinary Pathology*. 2025;24(4):43–54. <https://doi.org/10.23947/2949-4826-2025-24-4-43-54>

Оригинальное эмпирическое исследование

## Исследование морфофункционального состояния легких и центральных органов детоксикации джунгарских хомячков (*Phodopus sungorus*) при длительном воздействии аэрозоля электронных сигарет

А.В. Сахаров<sup>1</sup> , В.И. Бырдина<sup>1</sup> , П.А. Задубровский<sup>1,2</sup> , И.В. Задубровская<sup>1,2</sup>  , О.Ф. Потапова<sup>2</sup> , Е.Ю. Кондратюк<sup>3</sup> , С.С. Бондаренко<sup>4</sup>, Е.А. Новиков<sup>2,5</sup> 

<sup>1</sup>Новосибирский государственный педагогический университет, г. Новосибирск, Российская Федерация

<sup>2</sup>Институт систематики и экологии животных СО РАН, г. Новосибирск, Российская Федерация

<sup>3</sup>Научно-исследовательский институт клинической и экспериментальной лимфологии – филиал ФГБНУ «ФИЦ ИЦИГ СО РАН», г. Новосибирск, Российская Федерация

<sup>4</sup>Санкт-Петербургский государственный технологический институт, г. Санкт-Петербург, Российская Федерация

<sup>5</sup>Новосибирский государственный аграрный университет, г. Новосибирск, Российская Федерация

✉ [inna\\_zadubrovskaya@mail.ru](mailto:inna_zadubrovskaya@mail.ru)

### Аннотация

**Введение.** Многокомпонентный состав жидкостей для электронных систем доставки никотина (ЭСДН) представляет большую опасность для экологии, так как содержит чрезвычайно токсичные вещества. Несмотря на растущую популярность этого вида курения, данных о биологических эффектах длительного влияния состава электронных сигарет и вейпов на организм животных и человека недостаточно. Цель настоящей работы — исследовать морфофункциональное состояние легких и центральных органов детоксикации джунгарских хомячков при длительном воздействии аэрозоля ЭСДН.

**Материалы и методы.** Работа выполнена в 2021 г. на лабораторной колонии джунгарского хомячка, содержащейся на базе ИСиЭЖ СО РАН. 36 хомячков разделили на две группы. Животных опытной группы (10 самок и 10 самцов) в течение 80 дней подвергали воздействию пара, полученного при нагревании жидкости X-3 Yoghurt Rear. Процедуру проводили каждый день в течение 10 мин, по 2 раза с интервалом в 2 ч. Хомячков контрольной группы (8 самцов и 8 самок) помещали в затравочные камеры, но не подвергали воздействию пара. По завершении 80 дней эксперимента производили декапитацию животных и забор органов для изготовления микросрезов. Обзорные препараты окрашивали гематоксилином Бемера и эозином. Распределение коллагена определяли по методу Маллори. Гистологические препараты органов изучали в проходящем свете с помощью микроскопа.

**Результаты исследования.** У животных опытной группы в результате экспозиции токсичным паром выявлено наличие гомогенного вещества черного цвета среди клеток эпителия бронхов и в интерстиции альвеолярных мешочков. В паренхиме легкого обнаружены признаки развивающейся интерстициальной пневмонии, ателектаза и эмфиземы, обструктивного бронхита, что свидетельствует о нарушении вентиляционно-перфузионных отношений в легочной ткани и газообмена. В почках локализация гомогенного вещества отмечена в просвете канальцев нефрона. На светооптическом уровне основные признаки летального повреждения характерны для клеток нефротелия. Ярко выраженная дилатация капилляров почечного клубочка в совокупности со снижением площади почечных телец практически в 2 раза, по сравнению с контрольными образцами, указывает на нарушение гемодинамики и реабсорбционно-фильтрационной функции почек. В печени высокий уровень локализации гибнущих апоптозом темных гепатоцитов центральнобулярной зоны дольки, эволюционно приспособленных к детоксикации, указывает на причастность к этому процессу токсических веществ, поступающих в печень с кровью.

**Обсуждение и заключение.** В ходе эксперимента доказано общепатогенное воздействие аэрозоля ЭСДН на легкие и органы детоксикации животных при длительном применении. Подобные исследования необходимы в условиях наблюдающегося роста потребления данных средств доставки никотина на мировом рынке.

**Ключевые слова:** электронные системы доставки никотина, ЭСДН, аэрозоль электронных сигарет, вейпы, джунгарские хомячки, длительное воздействие, морфофункциональные изменения, лёгкие и органы детоксикации, почечная недостаточность, апоптоз гепатоцитов

**Декларация о соблюдении принципов Европейской конвенции о защите позвоночных животных, используемых для экспериментов и других научных целей:** авторы заявляют, что все проведенные исследования соответствовали принципам конвенции и правилам надлежащей лабораторной практики.

**Благодарности.** Выражаем благодарность за помощь в подготовке статьи студентам НГПУ Токаревой Дарье, Толстовой Дарье, Зезюлиной Екатерине.

**Финансирование.** Работа выполнена в рамках Федеральной программы фундаментальных научных исследований на 2021–2025 гг. FWGS -2021-0003.

**Для цитирования.** Сахаров А.В., Бырдина В.И., Задубровский П.А., Задубровская И.В., Потапова О.Ф., Кондрачук Е.Ю., Бондаренко С.С., Новиков Е.А. Исследование морфофункционального состояния легких и центральных органов детоксикации джунгарских хомячков (*Phodopus sungorus*) при длительном воздействии аэрозоля электронных сигарет. *Ветеринарная патология*. 2025;24(4):43–54. <https://doi.org/10.23947/2949-4826-2025-24-4-43-54>

**Introduction.** Electronic nicotine delivery systems (ENDS) first became widely available in Europe in 2006 and turned into the most popular alternative to conventional cigarettes [1–6], especially among young people and adolescents of the age of 14 and older [1, 7–10]. The most hazardous for the environment are the multi-component electronic cigarette (EC) liquids, which contain more than 30 toxic chemicals, including carbonyl compounds (aldehydes, ketones), metals, propylene glycol, and glycerol [11–16]. Moreover, carbonyl compounds include extremely toxic substances such as acrolein (maximum permissible concentration (MPC) in air 0.03 mg/m<sup>3</sup>) and formaldehyde (MPC 0.05 mg/m<sup>3</sup>), which irritate the mucous membranes of internal organs, as a minimum [17]. Also, acrolein causes mutagenesis in bacteria and yeast, exhibits mutagenic properties in mammalian cell cultures, and reduces activity of some components of the immune defence [18].

Studies examining the effects of two essential components of ENDS—propylene glycol and glycerin—show that propylene glycol, when aerosolized into the alveoli, boosts the destruction of surfactant, which ensures lung compliance and prevents lung tissue adhesion. This effect leads to pulmonary collapse (atelectasis), while adjacent areas undergo compensatory overstretching, causing emphysema. Propylene glycol is also considered a stimulating factor in the formation of squamous cell metaplasia of the larynx. In rats subjected to inhaling glycerin vapour, metaplasia of epiglottal epithelium was observed [19]. It is also known that glycerin heated in an e-cigarette up to 500°C transforms into acrolein mentioned above.

Apart from the main components, the ENDS also use a variety of flavouring agents. The Generally Recognized as Safe (GRAS) list includes flavouring agents for ingestion, however, the number of studies on inhaling the aerosols containing such substances is few. For example, it has been

proven that inhalation of diacetyl contained in e-liquid causes obliterating bronchiolitis, the so-called “popcorn lung” disease (the phenomenon was identified in the early 2000s due to the mass illnesses of workers of popcorn factories) [20]. At some factories, diacetyl was replaced by acetylpropionyl, but even then, researchers from the US National Institute for Occupational Safety and Health (NIOSH) had to note significant deviations in the spirometry readings of workers at such factories [21, 22]. In ENDS, these substances are used to impart buttery or caramel flavour, although pulmonary toxicity of acetylpropionyl to mammals has been proven. For example, rats exposed to it developed fibrosis and necrosis of the respiratory tract tissue; in mice exposed to the inhalation test (methacholine challenge test) more severe bronchoconstriction was observed [23]. On the whole, despite more than 7000 ENDS flavours resulting from the range of flavouring agents available on the market [24], only three studies have been published on the effects of flavouring agents on the organism [15, 25, 26].

A considerable amount of information can be found in the literature on the effects of electronic cigarettes and vapes on the organism of mammals. For example, it has been proven that exposure to ENDS vapour altered pulmonary function in rats [27]; reduced the conductivity of ion channels in sheep bronchial epithelial cells, and also led to mucus hyperconcentration [28]. A significant increase in pro-inflammatory cytokines was recorded in the lungs of rats [29], as well as development of the lipoid pneumonia [30]. It was also found that steaming with nicotine-free liquid affected the vital organs, which manifested in interalveolar septa thickening in the lungs of rats, filling the bronchial tubes with mucus obstructing the lumen, and lymphoid infiltration in bronchial tubes. In the kidneys, a three-fold expansion of the lumens in the Shumlyansky-Bowman capsules was recorded, along with the damage of the renal corpuscles and the epithelium of the proximal tubules [31].

It was noted that numbers of bronchitis, pneumonia, and lung cancer have increased in dogs in large cities [32]. Several studies revealed the hepatotoxicity of e-cigarette liquids in rats [33]. However, the information on the biological effects of long-term use of e-cigarettes and vapes is insufficiently presented in the scientific literature.

The aim of the present study is to investigate the morphofunctional changes in the lungs and main organs of detoxification of Djungarian hamsters (*Phodopus sungorus*) during long-term exposure to e-cigarette and vape aerosols.

**Materials and Methods.** The research was conducted in 2021 at the Institute of Systematics and Ecology of Animals, Siberian Branch of Russian Academy of Sciences and the Experimental and Applied Biology Research and Educational Centre of Novosibirsk State Pedagogical University. The work was performed with the colony of laboratory Djungarian hamsters (*Ph. sungorus*) kept under 12L/12D photoperiod at a temperature of +22 °C in standard cages (26 × 36 × 20 cm). Experimental animals (n = 36) were randomly divided into experimental and control groups: the experimental group included 10 males and 10 females; the control group included 8 males and 8 females.

During 80 days of experiment, hamsters in the experimental group were exposed to vapour from heating X-3 Yoghurt Pear liquid (PRIDE VAPE, Russia) containing glycerin and propylene glycol in a 70/30 ratio, nicotine at a dose of 3 mg/ml, and “Yogurt” and “Pear” flavouring agents. The vapour exposure consisted of inflowing cigarette vapour by means of a pump and filling with it the entire chamber two times with a 5-minute interval. After 10 minutes, the animals were removed from the containers. The procedure was performed daily, twice a day, with a 2-hour interval. Hamsters from the control group were delivered to the experimental room after removing the air with aerosol particles from the room, and then placed in the challenge chambers without exposure to ENDS vapour.

The experimental setup included a container for animal exposure to vapour. For this purpose, the plastic food containers of the dimensions 10 x 17 x 4 cm, and volume of 0.7 l, with tight-fitting lids were used. To optimize the process, two containers connected with 4 mm hoses (Boutte, Italy) were used simultaneously. A pump (Intex, China) with a volume of V~1.594 l was used to pump aerosol into the chambers.

To study the morphofunctional state of the lungs and main organs of detoxification, the lungs, kidneys, and livers of the animals from both groups were collected after decapitation and fixed in 10% neutral formalin. Tissue samples of these organs were dehydrated and clarified in isopropyl alcohol in compliance with the tissue processing protocol. The test specimens were embedded in paraffin blocks, and afterwards the series of 6-µm-thick slices were cut using a SLEE Medical CUT 5062 rotary semiautomated microtome (SLEE Medical GmbH, Germany). These slices were mounted on glass slides using a 1:1 protein-glycerol mixture. The slides were stained with Böhmer’s hematoxylin and eosin. Collagen distribution was determined using the Mallory method [34].

Histological preparations of the organs were examined under transmission light microscope Axio Imager M2 with AxioVision Z2 M2 image analysing module (Carl Zeiss, Germany). Images were taken using an AxioCam HR CCD camera with Zen Lite software (Carl Zeiss, Germany). All images contained a scale bar.

Statistical data were processed by calculating arithmetic means ( $\bar{x}$ ) and their errors (S $\bar{x}$ ). Differences in parameters between the experimental group compared to those in the control group were assessed using the Student’s t-test and were considered significant at  $p \leq 0.05$ . All calculations were performed using commonly accepted formulas and Microsoft Excel 2010.

**Results.** The morphological pattern of the lung parenchyma of animals from the control group generally corresponded to the normal structure of this organ (Fig. 1 a, b, c). In the preparations stained with Böhmer’s hematoxylin and eosin, bronchi of various calibres were clearly visible (Fig. 1 a, c). In large bronchi, multilayered and columnar structure of epithelium was observed (Fig. 1 c). In the lumen, mucous secretion and weakly expressed desquamation of the epithelium were identified mainly at the site of transition of the terminal bronchioles into respiratory ones. Intralobular blood vessels were filled with blood plasma. The morphological pattern of the alveoli, which included capillary endothelial cells, type-1 and -2 alveolar cells, and macrophages, corresponded to the norm (Fig. 1 b, c) [35-36].

In the examined lung tissue specimens of animals from the experimental group, changes affecting the lung parenchyma and interstitium were detected. In the specimens, alternating foci of atelectasis and emphysema were visible (Fig. 2a). Complexes of desquamated epithelial cells were visible in the lumen of the bronchi and bronchioles (Fig. 2a, b). The epithelium of the mucous membrane had lost its multilayered structure. At high magnification, the columnar epithelial cells were noticed to lose their cilia. In the lamina propria of the mucous membrane, signs of edema and swelling of the fibrous components of connective tissue were visible. Blood vessels of the lamina propria were excessively dilated, filled with plasma and blood cells. Among the latter, leukocytes were identified (Fig. 2c).

The interalveolar septa and the walls of the alveolar sacs were thickened due to plasma impregnation and capillary congestion (Fig. 2a). Macrophages, segmented neutrophils, and lymphocytes were found in the alveolar lumens (Fig. 2c). A typical feature found in the lung specimens of animals from the experimental group was an excessive increase in the number of type-2 alveolar cells (Fig. 2c). Among type-1 epithelial cells, cells with pyknotic nuclei were often found. Capillaries and venules were congested. Perivascular connective tissue was loose and edematous. Endothelial cells of the alveolar capillaries were swollen. The nucleus was large, with a high content of heterochromatin, as a rule, and was bulged into the lumen of the capillaries (Fig. 2d).

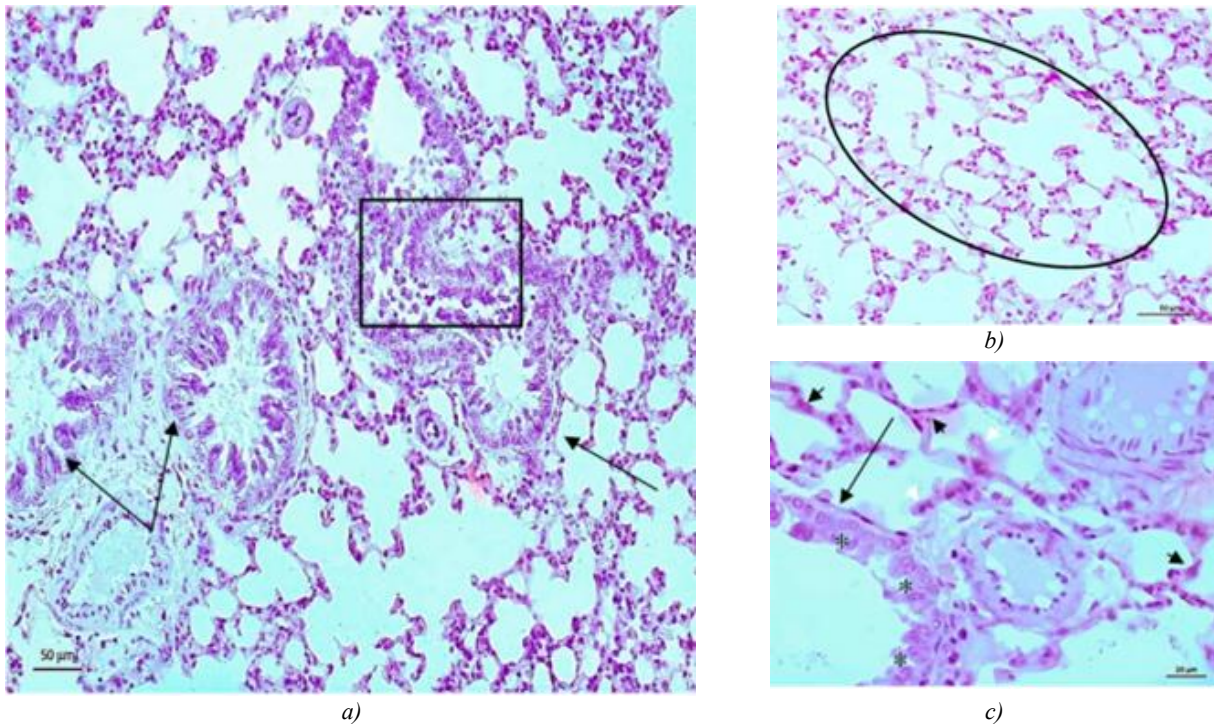


Fig. 1. Lung specimen of a Djungarian hamster from the control group. Stained with Böhmer's hematoxylin and eosin. Black arrow indicates bronchi; asterisk — columnar epithelium; black arrowhead — alveolar epithelium; light arrowhead — macrophages; oval — alveoli; square — epithelial desquamation

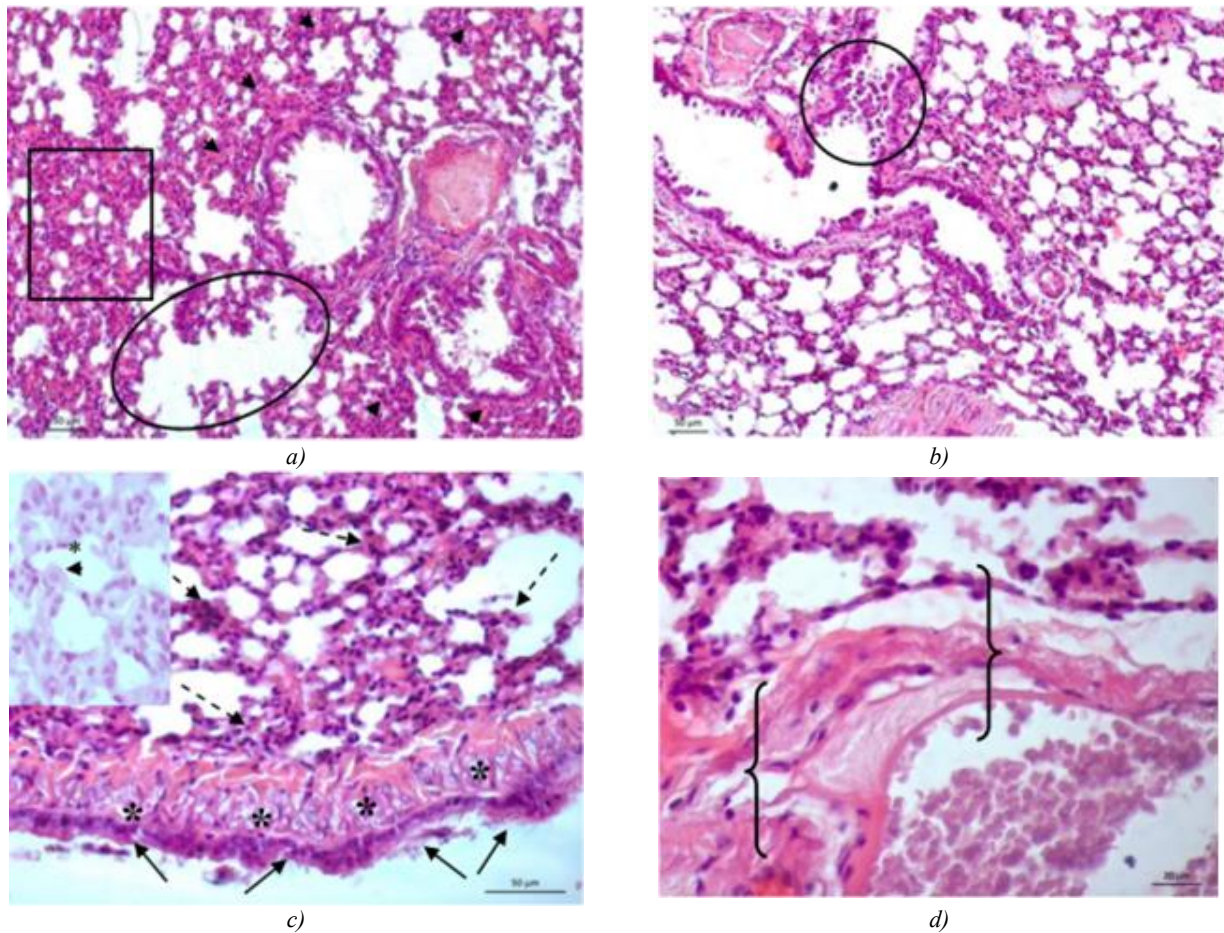


Fig. 2. Lung specimen of a Djungarian hamster from the experimental group. Stained with Böhmer's hematoxylin and eosin. The oval indicates an area of emphysema; the rectangle —atelectasis; the circle — epithelial desquamation; the black arrow — bronchial epithelium; the dotted arrow —leukocyte infiltration; the black arrowhead — plasma impregnation of the alveolar walls; the asterisk — edema of the lamina propria; the curly bracket — edema of the perivascular connective tissue. 2c: the black arrowhead indicates a type-2 alveolar cell; the asterisk — a type-1 alveolar cell

A typical feature of lung tissue in animals from the experimental group was localization of homogeneous black substance among bronchial epithelial cells and in the interstitium of the alveolar sacs (Fig. 3a). A histochemical reaction for collagen according to Mallory method revealed intense staining of slices for this protein in the stroma at the periphery of segmental, intrasegmental, and intralobular bronchi, arteries, and veins of the

lung. In the interstitium of the lung tissue, the reaction for collagen was moderate (Fig. 3b, c).

When studying kidney specimens of hamsters from the experimental group, a statistically significant decrease in all studied parameters of the renal glomeruli was found compared to the control group, which indicates a decrease in the functional activity of the kidneys in animals exposed to vapour (Table 1).

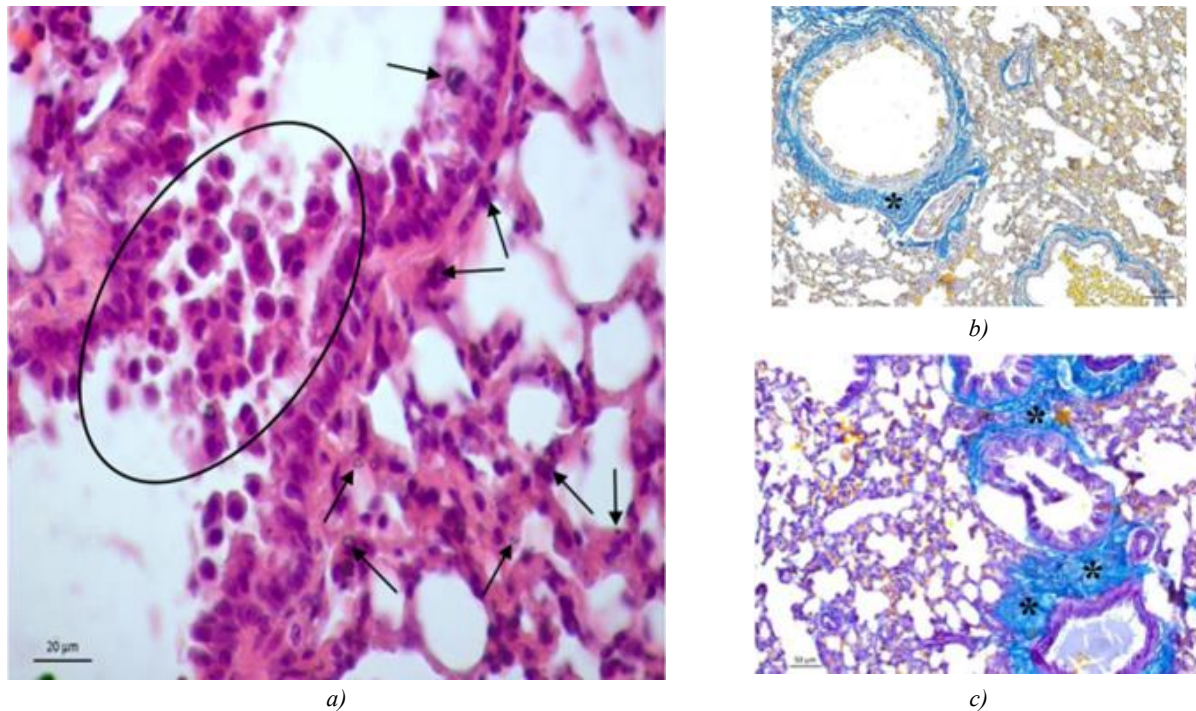


Fig. 3. Lung specimen of a Djungarian hamster from the experimental group: *a* — staining with Böhmer's hematoxylin and eosin; *b*, *c* — reaction for collagen according to Mallory method. The oval indicates the area of epithelial desquamation; the asterisk — positive reaction for collagen at the periphery of the segmental and intrasegmental bronchi; the black arrow — localization of homogeneous black substance

Table 1

Morphological features of the renal corpuscle structures

Renal corpuscle parameters	Control group	Experimental group
Renal corpuscle surface area, $\mu\text{m}^2$	$160.45 \pm 1.24$	$117.95 \pm 2.87^*$
Glomerulus size, $\mu\text{m}^2$	$131.97 \pm 0.12$	$95.34 \pm 0.17^*$
Urinary space, $\mu\text{m}^2$	$45.2 \pm 0.21$	$34.58 \pm 0.28^*$

Note: \* — differences between the parameters of the control and experimental groups were significant ( $p \leq 0.05$ )

The glomerular vessels were excessively dilated, filled with plasma and blood cells. Endothelial and mesangial cells were swollen, erythrocytes had signs of sludge phenomenon (Fig. 4b, d). A typical pathomorphological feature of kidney specimens of animals from the experimental group was a high content of nephrothelial cells with signs of lethal damage in all parts of the nephron. As a rule, the cytoplasm in dying nephrocytes does

not stain with hematoxylin and eosin, the nucleus is hyperchromatic, the nuclear membrane is not identifiable (Fig. 4a, c). In the lumen of the distal and proximal convoluted tubules, as well as in the cytoplasm of nephrocytes, a fine granular black substance was noticeable (Fig. 4c). This sign was especially pronounced in the lumen of the collecting ducts and among the epithelial cells of this part of the nephron (Fig. 4c).

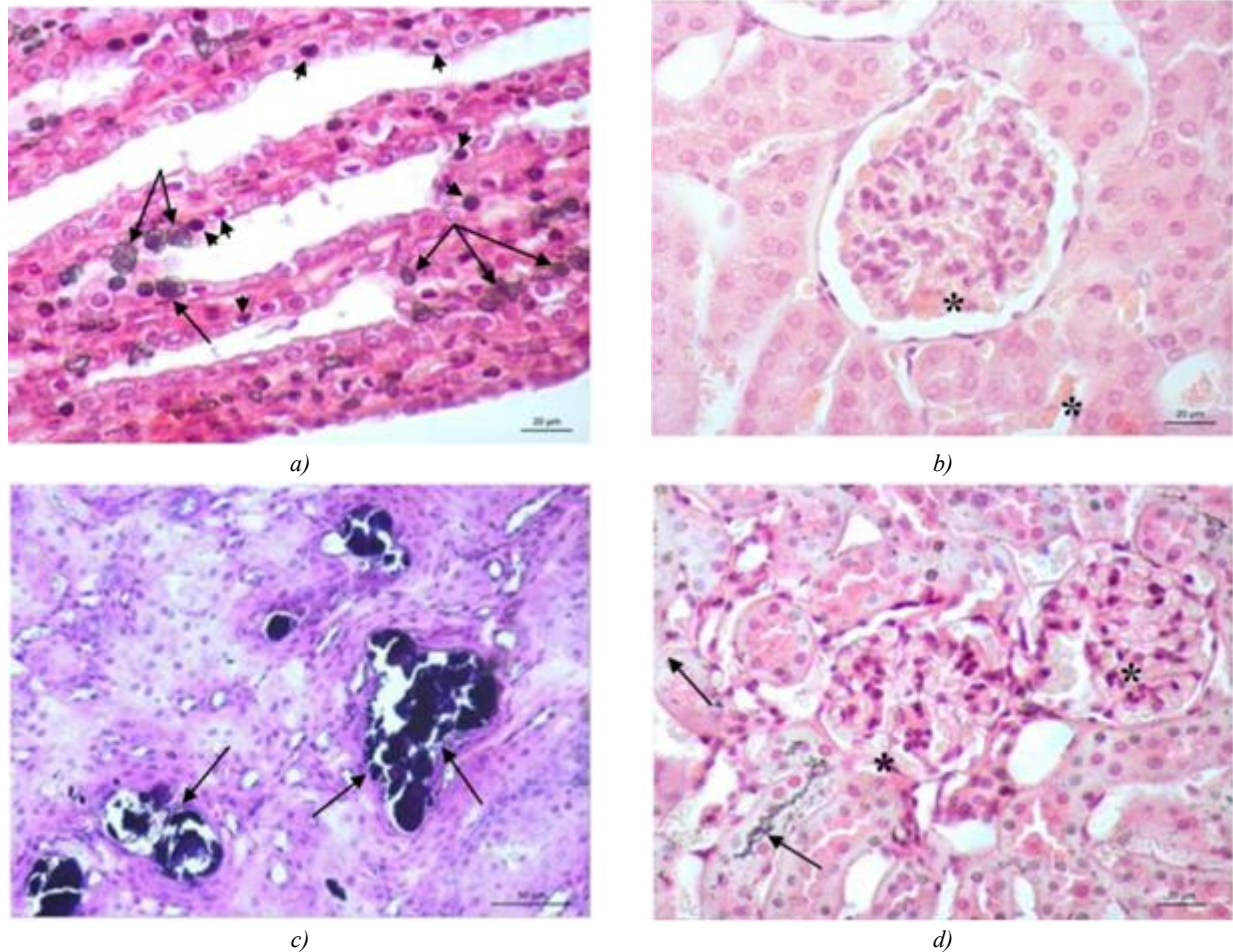


Fig. 4. Kidney specimen of a Djungarian hamster from the experimental group. Stained with Böhmer's hematoxylin and eosin. The black arrowhead indicates nephrocytes with signs of lethal damage; the black arrow — fine granular black substance; the asterisk — erythrocytes with signs of sludge phenomenon

At the light optical microscopy, hepatocytes of the centrilobular and periportal zones of the liver lobule of animals from the experimental group differed by tinctorial properties [37]. The cytoplasm of light hepatocytes was intensely basophilic and filled with oxyphilic material (Fig. 5a, c). In liver specimens of hamsters from the experimental group, stained with hematoxylin and eosin, compared to the control group, the predominance of hepatocytes with pycnotic nuclei in the organ parenchyma was clearly visible (Fig. 5a, b). Upon detailed examination of the specimens, it became obvious that such cells were hepatocytes dying by apoptosis. Their distinctive features were pycnosis of the cells and margination of chromatin in the nucleus (Fig. 5c). The predominance of such cells in the centrilobular zone, responsible for detoxification, suggested that the liver of animals in the experimental group experienced a functional load that was beyond the physiological optimum, and its adaptive resources were not capable of providing an adequate response to the effect of toxic substances (Fig. 5c).

**Discussion and Conclusion.** The results of the study provide every reason to consider that the chosen design of hamster exposure to the vape aerosol results in structural and functional changes in the lungs, liver, and kidneys. Damage to the bronchial epithelium, alveolar epithelium, and microcirculatory endothelium was detected in the

lungs. Light microscopy data do not allow us to identify damage to the structures of the air-blood barrier; however, the gross morphological changes detected in this compartment indicate a disruption in the structural and functional organization of the basal membranes of capillaries and epithelial cells. This is known to lead to impaired microcirculation in the lungs, increased permeability of pulmonary capillaries, and the development of pulmonary edema. This may explain the presence of interstitial and alveolar edema and distelectasis (alveolar collapse alternating with expansion) in the lung parenchyma, which develop with the participation of leukocytes and macrophages [38–39].

In accordance with complementarity principle, which postulates the unity of structure and function, the detected hemodynamic changes lead to the disruption of ventilation-perfusion relationships in lung tissue and to gas exchange disorder. The high level of type-2 alveolar cells in the tissue can be explained by an increase in their proliferative activity in response to damage to the alveolar epithelium by substances contained in the vape aerosol. In addition to their role in surfactant synthesis, type-2 alveolar cells are deemed to be ensuring the detoxification. The combination of the detected lung changes suggests the pathological features very similar to acute respiratory distress syndrome.

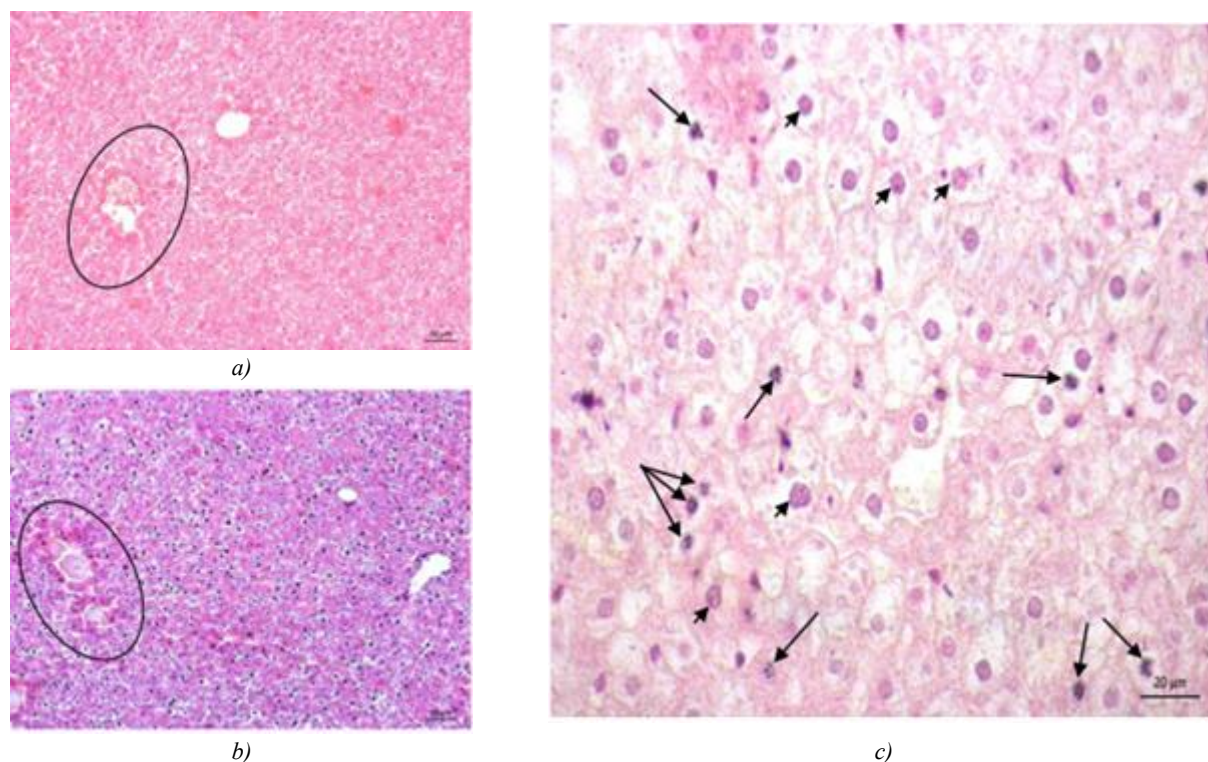


Fig. 5. Liver specimen of a Djungarian hamster from the experimental group. Stained with Böhmer's hematoxylin and eosin. The oval indicates the centrilobular zone of the liver lobule; the black arrow — hepatocytes with signs of apoptosis; the black arrowhead — hepatocytes with pyknotic nuclei

Excessive dilation of glomerular capillaries in the absence of hypercellularity and mesangial edema may be due to the direct impact of biologically active molecules on the capillary walls, leading to capillary damage and disruption of blood circulation. The presence of an unidentified homogeneous substance in the lumen of the proximal and distal sections of the nephron tubules and collecting ducts, suggests that this substance is transported through the glomerular basal membrane and enters the renal glomerulus from the general bloodstream. A decrease in the morphometric parameters of the structural

components of the renal corpuscle in the kidney specimens of animals from the experimental group, compared to the control group, provides every reason to suspect a disruption of the renal filtration-reabsorption mechanism and the development of renal failure.

Despite the absence of the obvious signs of liver damage, the abundance of evolutionarily adapted to detoxification dark hepatocytes dying by apoptosis in the centrilobular zone of the liver lobule, indicates the involvement of toxic substances in this process, which enter the liver with the blood.

## References

1. Rudakov NA. The History of the Creation and Promotion of Electronic Cigarettes. *Biznes-obrazovanie v ehkonomike znanii (Business Education in the Knowledge Economy)*. 2019;1(12):76–82. (In Russ.)
2. Oksuzyan AV, Dubinin OA, Khaliullina KR. Traumatic and Toxic Effects of Electronic Vaporizers on the Human Organism. *Modern Science*. 2021;21:235–237. (In Russ.)
3. Chadi N, Hadland SE, Harris SK. Understanding the Implications of the “Vaping Epidemic” among Adolescents and Young Adults: A Call for Action. *Substance Abuse*. 2019;40(1):7–10. <https://doi.org/10.1080/08897077.2019.1580241>
4. Cecchini MJ, Mukhopadhyay S, Arrossi AV, Beasley MB, Butt YM, Jones KD et al. E-Cigarette or Vaping Product Use-Associated Lung Injury: A Review for Pathologists. *Archives of Pathology and Laboratory Medicine*. 2020;(144(12)):1490–1500. <https://doi.org/10.5858/arpa.2020-0024-RA>
5. Schaffer S, Strang A, Saul D, Krishnan V, Chidekel A. Adolescent E-cigarette or Vaping Use-Associated Lung Injury in the Delaware Valley: A Review of Hospital-Based Presentation, Management, and Outcomes. *Cureus*. 2022;14(2):e21988. <https://doi.org/10.7759/cureus.21988>
6. Li Y, Dai J, Tran LN, Pinkerton KE, Spindel ER, Nguyen TB. Vaping Aerosols from Vitamin E Acetate and Tetrahydrocannabinol Oil: Chemistry and Composition. *Chemical Research in Toxicology*. 2022;35(6): 1095–1109. <https://doi.org/10.1021/acs.chemrestox.2c00064>
7. Melnikova IM, Dorovskaya NL, Sedova AP, Mizernitsky YuL. Structure of Consumption of Tobacco-Containing Products by Adolescents according to the Results of the Questionnaire. *Russian Bulletin of Perinatology and Pediatrics*. 2020;65(4):307. (In Russ.) <https://doi.org/10.21508/1027-4065-congress-2020>

8. Dai H, Leventhal AM. Association of Electronic Cigarette Vaping and Subsequent Smoking Relapse among Former Smokers. *Drug and Alcohol Dependence*. 2019;199:10–17. <https://doi.org/10.1016/j.drugalcdep.2019.01.043>
9. Gentzke AS, Creamer M, Cullen KA, Ambrose BK, Willis GB, Jamal A et al. Vital Signs: Tobacco Product Use Among Middle and High School Students — United States, 2011–2018. *MMWR. Morbidity and Mortality Weekly Report*. 2019;68(6):157–164. <https://doi.org/10.15585/mmwr.mm6806e1>
10. Burt B, Li J. The Electronic Cigarette Epidemic in Youth and Young Adults: A Practical Review. *JAAPA: official journal of the American Academy of Physician Assistants*. 2020;33(3):17–23. <https://doi.org/10.1097/01.JAA.0000654384.02068.99>
11. Bekki K, Uchiyama S, Ohta K, Inaba Y, Nakagome H, Kunugita N. Carbonyl Compounds Generated from Electronic Cigarettes. *International Journal of Environmental Research and Public Health*. 2014;11(11):11192–11200. <https://doi.org/10.3390/ijerph11111192>
12. Callahan-Lyon P. Electronic Cigarettes: Human Health Effects. *Tobacco Control*. 2014;23(Suppl. 2):ii36–ii40. <https://doi.org/10.1136/tobaccocontrol-2013-051470>
13. Cheng T. Chemical Evaluation of Electronic Cigarettes. *Tobacco Control*. 2014;23(Suppl.2):ii11– ii17. <https://doi.org/10.1136/tobaccocontrol-2013-051482>
14. Goniewicz M, Hajek P, McRobbie H. Nicotine Content of Electronic Cigarettes, Its Release in Vapour and Its Consistency across Batches: Regulatory Implications. *Addiction*. 2014;109(3):500–507. <https://doi.org/10.1111/add.12410>
15. Hutzler C, Paschke M, Krushinski S, Henkler F, Hahn J, Luch A. Chemical Hazards Present in Liquids and Vapors of Electronic Cigarettes. *Archives of Toxicology*. 2014;88(7):1295–1308. <https://doi.org/10.1007/s00204-014-1294-7>
16. Jensen PR, Luo W, Pankow JF, Strongin RM, Peyton DH. Hidden Formaldehyde in E-Cigarette Aerosols. *The New-England Journal of Medicine*. 2015;372(4):392–394. <https://doi.org/10.1056/NEJMc1413069>
17. Allen J, Montalto M, Lovejoy J, Weber W. Detoxification in Naturopathic Medicine: A Survey. *Journal of Alternative and Complementary Medicine (New York, N.Y.)*. 2011;17(12):1175–1180. <https://doi.org/10.1089/acm.2010.0572>
18. Lambert C, Li J, Jonscher K, Yang TC, Reigan P, Quintana M, et al. Acrolein Inhibits Cytokine Gene Expression by Alkylating Cysteine and Arginine Residues in the NF-kappaB1 DNA Binding Domain. *Journal of Biological Chemistry*. 2007;282(27):19666–19675. <https://doi.org/10.1074/jbc.M611527200>
19. Mukhopadhyay S, Mehrad M, Dammert P, Arrossi AV, Sarda R, Brenner DS, et al. Lung Biopsy Findings in Severe Pulmonary Illness Associated with E-Cigarette Use (Vaping). *American Journal of Clinical Pathology*. 2020;153(1):30–39. <https://doi.org/10.1093/ajcp/aqz182>
20. Hilts P. *Artificial Butter Suspected in Lung Disease*. New York: New York Times. 2001.
21. Boylstein R. Identification of Diacetyl Substitutes at a Microwave Popcorn Production Plant. *Case Study. Journal of Occupational and Environmental Hygiene*. 2012;9(2):D33–D34. <https://doi.org/10.1080/15459624.2011.639234>
22. Gaffney SH, Abelmann A, Pierce JS, Glynn ME, Henshaw JL, McCarthy LA, et al. Naturally Occurring Diacetyl and 2,3-Pentanedione Concentrations Associated with Roasting and Grinding Unflavored Coffee Beans in a Commercial Setting. *Toxicology Report*. 2015;2:1171–1181. <https://doi.org/10.1016/j.toxrep.2015.08.003>
23. Holden VK, Hines SE. Update on Flavoring-Induced Lung Disease. *Current Opinion in Pulmonary Medicine*. 2016;22(2):158–164. <https://doi.org/10.1097/MCP.0000000000000250>
24. Zhu SH, Sun JY, Bonnevie E, Cummins SE, Gamst A, Yin L, et al. Four Hundred and Sixty Brands of E-Cigarettes and Counting: Implications for Product Regulation. *Tobacco Control*. 2014;23(Suppl. 3):iii3–iii9. <https://doi.org/10.1136/tobaccocontrol-2014-051670>
25. Behar RZ, Davis B, Wang Y, Bahl V, Lin S, Talbot P. Identification of Toxicants in Cinnamon-Flavored Electronic Cigarette Refill Fluids. *Toxicology in Vitro*. 2014;28(2):198–208. <https://doi.org/10.1016/j.tiv.2013.10.006>
26. Farsalinos K.E., Voudris V., Poulas K. E-Cigarettes Generate High Levels of Aldehydes Only in 'Dry Puff' Conditions. *Addiction*. 2015;110(8):1352–1356. <https://doi.org/110.1111/add.12942>
27. Phillips B, Titz B, Kogel U, Sharma D, Leroy, P, Xiang Y, et al. Toxicity of the main Electronic Cigarette Components, Propylene Glycol, Glycerin, and Nicotine, in Sprague-Dawley Rats in a 90-day OECD Inhalation Study Complemented by Molecular Endpoints. *Food and Chemical Toxicology*. 2017;109(Pt1):315–332. <https://doi.org/10.1016/j.fct.2017.09.001>
28. Kim MD, Chung S, Baumlin N, Qian J, Montgomery RN, Sabater J, et al. The Combination of Propylene Glycol and Vegetable Glycerin E-Cigarette Aerosols Induces Airway Inflammation and Mucus Hyperconcentration. *Scientific Reports*. 2024;14(1):1942. <https://doi.org/10.1038/s41598-024-52317-8>
29. Wawryk-Gawda E, Zarobkiewicz MK, Wolanin-Stachyra M, Opoka-Winiarska V. Inflammatory Markers Activation Associated with Vapor or Smoke Exposure in Wistar Rats. *Frontiers in Immunology*. 2025;16:1525166. <https://doi.org/10.3389/fimmu.2025.1525166>
30. Matsumoto S, Traber M, Leonard SW, Choi J, Fang X, Maishan M, et al. Aerosolized Vitamin E Acetate Causes Oxidative Injury in Mice and in Alveolar Macrophages. *American Journal of Physiology*. 2022;322(6):771–783. <https://doi.org/10.1152/ajplung.00482.2021>

31. Matveevskaya DA, Kondratieva EV, Osloпова AA, Solonenko MA, Pavlichenko EV. The Effect of Nicotine-Free Vaping on the Morphology of Some Organs in the Experiment. In: *Proceedings of the XVII Interregional Scientific and Practical Conference of Students and Young Scientists "Medicine of Tomorrow" Dedicated to the 65<sup>th</sup> Anniversary of the Chita State Medical Academy. Chita, April 17–20, 2018*. Chita: Editorial and Publishing Center of Chita State Medical Academy; 2018. P. 268–269.
32. Shchukin MV, Sodboev TsTs, Sheshenin MD. The Influence of the Ecological Situation of the Metropolis on the Pathology of the Respiratory Organs in Dogs. In: *Proceedings of the II National Scientific and Practical Conference "Commodity Science, Technology, and Expertise: Innovative Solutions and Development Prospects". Moscow, June 1, 2021*. Moscow: Moscow State Academy of Veterinary Medicine and Biotechnology — MVA Named after K. I. Skryabin; 2021. P. 327–332.
33. Androsova OG, Allazov DR, Zinin MS. Effects of Electronic Cigarettes on the Liver (Literature Review). *Bulletin of Physiology and Pathology of Respiration*. 2025;(96):154–163. (In Russ.) <https://doi.org/10.36604/1998-5029-2025-96-154-163>
34. Semchenko VV, Barashkova SA, Nozdrin VI, Artemyev VN. *Histological Technique: A Tutorial*. Omsk, Orel: Omsk Regional Printing House; 2006. 289 p. (In Russ.)
35. Shemyakov SE, Fedosov AA. Anatomy and Histology of Lungs, Chapter I. In book: *Respiratory Medicine: Guidebook: In 5 Volumes*. Moscow: PulmoMedia; 2024. 668 p. (In Russ.) <https://doi.org/10.18093/987-5-6048754-9-0-2024-1-18-47>
36. Pawlina W, Ross MH. *Histology: A Text and Atlas: With Correlated Cell and Molecular Biology. 8th Ed.* USA: LWW Publ.; 2018.
37. Aminova GG. What Need Consider as a Structural and Functional Unit of the Human Liver? *Morphological Newsletter*. 2018;26(4):35–38. (In Russ.)
38. Paltsev MA, Paukov VS, Ulunbekov EG (Eds.). *Pathology: Guidebook*. Moscow: GEOTAR-MED; 2002. 960 p.
39. Manskikh VN. Technical Aspects. General and Organ Pathology. Vol. 1. In book: *Pathomorphology of Laboratory Mouse: in 3 Volumes*. Moscow: VAKO; 2016:208 p. (In Russ.)

**About the Authors:**

**Andrey V. Sakharov**, Dr.Sci.(Biology), Associate Professor, Head of the Biology and Ecology, Department, Novosibirsk State Pedagogical University (28, Vilyuyskaya Str., Novosibirsk, 630126, Russian Federation), [SPIN-code](#), [ORCID](#), [Researcher ID](#), [Scopus ID](#)

**Vitalina I. Byrdina**, Cand.Sci.(Biology), Associate Professor of the Biology and Ecology Department of the Institute of Natural and Socio-Economic Sciences, Novosibirsk State Pedagogical University (28, Vilyuyskaya Str., Novosibirsk, 630126, Russian Federation), [SPIN-code](#), [ORCID](#), [Researcher ID](#)

**Pavel A. Zadubrovsky**, Cand.Sci.(Biology), Senior Research Associate at the Laboratory of Structure and Dynamics of Vertebrate Animal Populations, Institute of Systematics and Ecology of Animals, Siberian Branch of Russian Academy of Sciences (11, Frunze Str., Novosibirsk, 630091, Russian Federation); Lecturer of the Biology and Ecology Department of the Institute of Natural and Socio-Economic Sciences, Novosibirsk State Pedagogical University (28, Vilyuyskaya Str., Novosibirsk, 630126, Russian Federation), [SPIN-code](#), [ORCID](#), [Researcher ID](#), [Scopus ID](#), [etolog@mail.com](mailto:etolog@mail.com)

**Inna V. Zadubrovskaya**, Cand.Sci. (Biology), Senior Research Associate at the Laboratory of Structure and Dynamics of Vertebrate Animal Populations, Institute of Systematics and Ecology of Animals, Siberian Branch of Russian Academy of Sciences (11, Frunze Str., Novosibirsk, 630091, Russian Federation); Associate Professor of the Biology and Ecology Department of the Institute of Natural and Socio-Economic Sciences, Novosibirsk State Pedagogical University (28, Vilyuyskaya Str., Novosibirsk, 630126, Russian Federation), [SPIN-code](#), [ORCID](#), [Researcher ID](#), [Scopus ID](#), [inna\\_zadubrovskaya@mail.ru](mailto:inna_zadubrovskaya@mail.ru)

**Olga F. Potapova**, Research Associate at the Laboratory of Structure and Dynamics of Vertebrate Animal Populations, Institute of Systematics and Ecology of Animals, Siberian Branch of Russian Academy of Sciences (11, Frunze Str., Novosibirsk, 630091, Russian Federation), [SPIN-code](#), [ORCID](#), [Scopus ID](#), [ofpotapova@yandex.ru](mailto:ofpotapova@yandex.ru)

**Ekaterina Yu. Kondratyuk**, Cand.Sci.(Biology), Research Associate at the Research Institute of Clinical and Experimental Lymphology – Branch of Institute of Cytology and Genetics, Siberian Branch of Russian Academy of Sciences (6, Arbuzov Str., Novosibirsk, 630117, Russian Federation), [SPIN-code](#), [ORCID](#), [Researcher ID](#), [Scopus ID](#)

**Sergey S. Bondarenko**, Postgraduate Degree Student, Saint Petersburg State Institute of Technology (24–26/49, Moskovsky Ave., St. Petersburg, 190013, Russian Federation), [sergeib@mail.ru](mailto:sergeib@mail.ru)

**Evgeny A. Novikov**, Dr.Sci. (Biology), Head of the Laboratory of Structure and Dynamics of Vertebrate Animal Populations, Institute of Systematics and Ecology of Animals, Siberian Branch of Russian Academy of Sciences (11, Frunze Str., Novosibirsk, 630091, Russian Federation); Head of the Ecology Department, Novosibirsk State Agrarian University (160, Dobrolyubova Str., Novosibirsk, 630039, Russian Federation), [SPIN-code](#), [ORCID](#), [Researcher ID](#), [Scopus ID](#), [eug-nov5@yandex.ru](mailto:eug-nov5@yandex.ru)

*Claimed Contributorship:*

**AV Sakharov:** provision of resources, scientific supervision, writing the manuscript.

**VI Byrdina:** conducting research, visualization, writing the manuscript.

**PA Zadubrovsky:** development of the concept, data monitoring, formalized analysis, conducting research, provision of resources, validating the results.

**IV Zadubrovskaya:** conducting research, writing a draft manuscript, editing the manuscript.

**OF Potapova:** conducting research

**EYu Kondratyuk:** conducting research.

**SS Bondarenko:** development of the concept, conducting research, development of research methodology.

**EA Novikov:** obtaining funding, administrative management of the research project, provision of resources.

**Conflict of Interest Statement:** the authors declare no conflict of interest.

*All authors have read and approved the final manuscript.*

*Об авторах:*

**Андрей Валентинович Сахаров**, доктор биологических наук, доцент, заведующий кафедрой биологии и экологии Новосибирского государственного педагогического университета (630126, Российская Федерация, г. Новосибирск, ул. Вилюйская, 28), [SPIN-код](#), [ORCID](#), [Researcher ID](#), [Scopus ID](#)

**Виталина Игоревна Бырдина**, кандидат биологических наук, доцент кафедры биологии и экологии Института естественных и социально-экономических наук Новосибирского государственного педагогического университета, (630126, Российская Федерация, г. Новосибирск, ул. Вилюйская, 28), [SPIN-код](#), [ORCID](#), [Researcher ID](#)

**Павел Александрович Задубровский**, кандидат биологических наук, старший научный сотрудник Лаборатории структуры и динамики популяций позвоночных животных Института систематики и экологии животных (630091, Российская Федерация, г. Новосибирск, ул. Фрунзе, 11), преподаватель кафедры биологии и экологии Института естественных и социально-экономических наук Новосибирского государственного педагогического университета (630126, Российская Федерация, г. Новосибирск, ул. Вилюйская, 28), [SPIN-код](#), [ORCID](#), [Researcher ID](#), [Scopus ID](#), [etolog@mail.com](mailto:etolog@mail.com)

**Инна Валерьевна Задубровская**, кандидат биологических наук, старший научный сотрудник Лаборатории структуры и динамики популяций позвоночных животных Института систематики и экологии животных (630091, Российская Федерация, г. Новосибирск, ул. Фрунзе, 11), доцент кафедры биологии и экологии Института естественных и социально-экономических наук Новосибирского государственного педагогического университета (630126, Российская Федерация, г. Новосибирск, ул. Вилюйская, 28), [SPIN-код](#), [ORCID](#), [Researcher ID](#), [Scopus ID](#), [inna\\_zadubrovskaya@mail.ru](mailto:inna_zadubrovskaya@mail.ru)

**Ольга Федоровна Потапова**, научный сотрудник Лаборатории структуры и динамики популяций позвоночных животных Института систематики и экологии животных (630091, Российская Федерация, г. Новосибирск, ул. Фрунзе, 11), [SPIN-код](#), [ORCID](#), [Scopus ID](#), [ofpotapova@yandex.ru](mailto:ofpotapova@yandex.ru)

**Екатерина Юрьевна Кондратюк**, кандидат биологических наук, научный сотрудник Научно-исследовательского института клинической и экспериментальной лимфологии – филиал Федерального исследовательского центра Института цитологии и генетики СО РАН (630117, Российская Федерация, г. Новосибирск, ул. Арбузова, 6), [SPIN-код](#), [ORCID](#), [Researcher ID](#), [Scopus ID](#)

**Сергей Сергеевич Бондаренко**, аспирант Санкт-Петербургского государственного технологического института (технический университет) (190013, Российская Федерация, г. Санкт-Петербург, Московский пр., 24–26/49), [cergeib@mail.ru](mailto:cergeib@mail.ru)

**Евгений Анатольевич Новиков**, доктор биологических наук, заведующий Лабораторией структуры и динамики популяций позвоночных животных Института систематики и экологии животных (630091, Российская Федерация, г. Новосибирск, ул. Фрунзе, 11), заведующий кафедрой экологии Новосибирского государственного аграрного университета, (630039, Российская Федерация, г. Новосибирск, ул. Добролюбова, 160), [SPIN-код](#), [ORCID](#), [Researcher ID](#), [Scopus ID](#), [eug-nov5@yandex.ru](mailto:eug-nov5@yandex.ru)

***Заявленный вклад авторов:***

**А.В. Сахаров:** предоставление ресурсов, научное руководство, написание рукописи.

**В.И. Бырдина:** проведение исследования, визуализация, написание рукописи.

**П.А. Задубровский:** разработка концепции, курирование данных, формальный анализ, проведение исследования, предоставление ресурсов, валидация результатов.

**И.В. Задубровская:** проведение исследования, написание черновика рукописи, редактирование рукописи.

**О.Ф. Потапова:** проведение исследования.

**Е.Ю. Кондратюк:** проведение исследования.

**С.С. Бондаренко:** разработка концепции, проведение исследования, разработка методологии.

**Е.А. Новиков:** получение финансирования, административное руководство исследовательским проектом, предоставление ресурсов.

***Конфликт интересов:*** авторы заявляют об отсутствии конфликта интересов.

***Все авторы прочитали и одобрили окончательный вариант рукописи.***

**Received / Поступила в редакцию 24.09.2025**

**Reviewed / Поступила после рецензирования 23.10.2025**

**Accepted / Принята к публикации 28.10.2025**