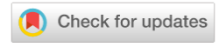

PARASITOLOGY

ПАРАЗИТОЛОГИЯ






UDC 619:616.995.122

<https://doi.org/10.23947/2949-4826-2026-25-1-7-16>

Original Empirical Research

Prevalence of Trematodes of the Family Notocotylidae in the Perm Territory

 Tatiana N. Sivkova , Darya A. Lokteva , Margarita V. Khazova 

Perm State Agro-Technological University Named after Academician D.N. Pryanishnikov, Perm, Russian Federation

 ✉ tatiana-sivkova@yandex.ru


EDN: LKXCIS

Abstract

Introduction. Notocotylidoses are fairly widespread in Russia dioxenous trematode diseases of birds and some mammals caused by the members of the family Notocotylidae, which parasitize in the intestines. Although the Perm Territory conditions (hydrological situation, prevalence of susceptible hosts) are apt to the increase of the population of this trematode species, the epizootic situation for this trematode in the region remains unstudied. The aim of the article is to investigate the prevalence of trematodes of the family Notocotylidae in the Perm Territory.

Materials and Methods. The objects of the study were freshwater gastropods (n=340), cadavers of wild waterfowl (n=16) and samples of mallards' droppings from the places of their aggregations (n=139) collected in the Perm Territory during the warm seasons of 2024 and 2025. The research was carried out at Perm State Agro-Technological University named after Academician D.N. Pryanishnikov in compliance with the standard techniques: using microscopy compressor; partial helminthological dissections; sequential washings of droppings; standard histological examination of tissues of infested mollusks and ducks.

Results. A single *Anisus vortex* specimen from the Motovilikha Pond (Perm) was found to be infested with cercaria of *Notocotylus sp.* Also, marita of *N. attenuatus* was found in the intestines of a *Clangula hyemalis*. In the histological samples of the infested mollusk, edema, friable tissues, mucin hypersecretion were revealed, and single cercariae were isolated. Also, the exposure of bird's intestines to *N. attenuatus* resulted in chronic condition manifested in edema and degenerative changes in the tissues, as well as the development of the macrophage response in the lymph nodes.

Discussion and Conclusion. The presence of larval notocotylids in the Perm Territory did not confirm having a natural focus of avian notocotylidosis there. In this case, mammals are likely to be the definitive hosts. Marita of *N. attenuatus* was detected in a migratory species, in the long-tailed duck, which might have been infested in its wintering or nesting areas.

Keywords: notocotylids, Notocotylidae, trematodes, prevalence, birds, mollusks, histological changes, Perm Territory

For Citation. Sivkova TN, Lokteva DA, Khazova MV. Prevalence of Trematodes of the Family Notocotylidae in the Perm Territory. *Russian Journal of Veterinary Pathology*. 2026;25(1):7–16. <https://doi.org/10.23947/2949-4826-2026-25-1-7-16>

Оригинальное эмпирическое исследование

Распространенность трематод семейства Notocotylidae на территории Пермского края

 Т.Н. Сивкова , Д.А. Локтева , М.В. Хазова 

Пермский государственный аграрно-технологический университет имени академика Д.Н. Прянишникова, г. Пермь, Российская Федерация

 ✉ tatiana-sivkova@yandex.ru

Аннотация

Введение. Нотокотилидозы — довольно распространенные в России диксенные трематодозы птиц и некоторых млекопитающих, вызываемые представителями семейства Notocotylidae, паразитирующими в кишечнике. Несмотря на присутствующие в Пермском крае благоприятные факторы роста численности этого вида трематод

(гидрология, распространенность восприимчивых хозяев), эпизоотическая ситуация по ним в регионе на данный момент остается неизученной. Цель статьи — исследовать распространенность трематод семейства Notocotylidae на территории Пермского края.

Материалы и методы. Объектом исследования стали пресноводные брюхоногие моллюски (n=340), трупы диких водоплавающих птиц (n=16) и пробы помёта из мест скопления крякв (n=139), собранные на территории Пермского края в теплый сезон 2024 и 2025 гг. Исследования осуществлялись в ПГАТУ имени Д.Н. Прянишникова согласно общепринятым методикам: компрессорная микроскопия; метод неполных гельминтологических вскрытий; последовательные промывания помёта; стандартное гистологическое исследование тканей инвазированных моллюсков и утиных.

Результаты исследования. Выявлена инвазия церкариями *Notocotylus sp.* одного экземпляра *Anisus vortex* из Мотовилихинского пруда (г. Пермь), а также марита *N. attenuatus* в кишечнике у *Clangula hyemalis*. Гистологические препараты инвазированного моллюска показали отёчность, разволокнение тканей, гиперсекрецию муцина, также выявлены отдельные церкарии. Воздействие *N. attenuatus* на кишечник птицы также оказалось хроническим и проявилось отёком и дистрофическими изменениями в тканях, развитием макрофагальной реакции в лимфатических узлах.

Обсуждение и заключение. Наличие личинок нотокотилид на территории Пермского края не подтвердило природный очаг нотокотилидоза птиц. Вероятно, дефинитивным хозяином в данном случае выступают млекопитающие. Марита *N. attenuatus* выявлена у пролетного вида — морянки, которая могла быть инвазирована в местах зимовки или гнездования.

Ключевые слова: нотокотилиды, Notocotylidae, трематоды, распространенность, птицы, моллюски, гистологические изменения, Пермский край

Для цитирования. Сивкова Т.Н., Локтева Д.А., Хазова М.В. Распространенность трематод семейства Notocotylidae на территории Пермского края. *Ветеринарная патология.* 2026;25(1):7–16. <https://doi.org/10.23947/2949-4826-2026-25-1-7-16>

Introduction. According to the modern understanding, trematodes are parasitic organisms that had appeared in the Cambrian period and currently consist of more than 2 700 nominal genera and approximately 18 000 species [1] and parasitize in fish, amphibians, reptiles, birds, mammals, and humans. Most of them are characterised by dioxenous or trioxenous life cycles, and involve gastropods as intermediate hosts. Many of them are the causative agents of diseases in agricultural and domestic animals, as well as in humans, and, therefore, are being actively and comprehensively studied. Particular attention is usually paid to such diseases as opisthorchiasis, fascioliasis, clonorchiasis, paragonimiasis, schistosomiasis, etc., however, some infestations remain insufficiently studied.

One of such poorly studied infestations are notocotylidoses — the trematodiasis in animals caused by parasitism of the representatives of the family Notocotylidae, which are registered in the intestines of many bird species, as well as in some mammals [2–6]. From the economic point of view, notocotylidoses cause significant damage to poultry reared at the farms and to some species of game birds. Parasitic worms cause mechanical damage to the intestinal mucosa and facilitate penetration of microorgan-

isms into the intestinal wall. Despite the fact that the morphology, life cycles and molecular analysis of notocotylids attract the attention of specialists of the relevant fields [7, 8], pathoanatomical changes caused by Notocotylidae are poorly described. The Manual on Veterinary Parasitology specifies that in trematodiasis cause the catarrhal or catarrhal-hemorrhagic inflammation of the cecum and rectum mucous membrane; at the sites of parasite attachment, the epithelium is destroyed and ulcers appear; in the infested mollusks, the reaction is formed in response to the invasion and development of trematode larval stages [9]. However, no likewise information could be found in the literature with regard to infestation by the representatives of the family Notocotylidae.

Notocotylidoses had been widely spread in Russia since long ago. In earlier publications, the infestations were reported to be revealed in Western Siberia [10], in the Caucasus [11], in the European North of the country [2, 12] and in some other regions. In the Perm Territory, there are more than 29 000 rivers with a total length of about 90 000 km, about 115 lakes (with an area of more than 10 hectares), 18 reservoirs, including the large ones such as Kama and Votkinsk reservoirs, and numerous ponds¹. The malacofauna in the Upper and Middle Kama

¹ According to the Data of the Ministry of Natural Resources and Environment of the Russian Federation (Perm Territory). <https://priroda.permkrai.ru/?ysclid=mmoxx4z0we339984914> (accessed: 5.11.2025)

basin alone includes 97 species of 30 genera and 10 families of the classes Bivalvia and Gastropoda. The most diverse are the families Sphaeriidae (29 species), Lymnaeidae and Planorbidae (21 species each) [13]. The avifauna of the region is also rich [14, 15]: according to official data of the Ministry of Natural Resources and Environment for 2024, there were 71 846 ducks and 4 665 geese registered in the Perm Territory².

Despite the abundance of water resources, wide spreading of specific hosts, and possibility of infestation to circulate in natural foci, no targeted study of the prevalence of notocotylidoses in the Perm Territory has been conducted, which served the rationale for the present work.

Materials and Methods. The research was conducted at the Department of Infectious Diseases of Perm State Agro-Technological University named after Academician D.N. Pryanishnikov. Due to the notocotylids' having dioxenous life cycle, the following materials were taken for the study: freshwater mollusks (n=340); cadavers of wild waterfowl that died for various reasons (n=16); droppings samples (n=139) collected in mallard aggregation areas. 39 locations of various water bodies in several districts of Perm Territory and the city of Perm were explored during the warm seasons of 2024 and 2025 to collect the material: Raiskii sad (Motovilikha Pond), Danilikha River, Zoloty Peski, Parkovyi and Lipovaya gora districts. All locations are characterized by free access to water and abundant fauna and flora. Mollusks were collected manually, and their species membership was determined by the authors themselves based on conchological features using open-access species identification key [16–18]. Shell height and width, and shell mouth width were measured using a TOPEX callipers (Poland). Compressor microscopy was then performed using a MIS-7 compressor ("Petrolazer", Russia) and a Mikromed MS-1 stereomicroscope ("Micromed", Russia). The shells were additionally examined with a binocular magnifying glass to detect larval forms of trematodes.

Until being provided to ornithologists for autopsy, the wild duck cadavers were stored at -18°C . Autopsy was performed according to the standard technique.

The locations of collecting the material and amounts of material collected for examination are presented in Table 1.

For histological examination, mollusk tissues were placed in the formalin solution with 4% formaldehyde con-

tent; birds' autopsy specimens were placed in the 10% formaldehyde solution. Hematoxylin-eosin-stained specimens were scanned and viewed using the Vision Assist automated system (West Medica, Austria) and Vision microscopy automation software ("Medica Product", Russia).

Droppings samples were analysed using sequential washing technique. Helminth eggs were identified by morphological characteristics [19].

Research Results. The study of 15 specimens of Whirlpool ramshorn snail (*Anisus vortex*) from the Motovilikha Pond (Perm), collected in the first ten days of June, resulted in detecting the cercariae with the morphological characteristics of *Notocotylus sp.* in one of the cases (Fig. 1). The infestation extensity (IE) in Planorbidae from the Motovilikha Pond was 6.67%. The distribution of *A. vortex* from the Motovilikha Pond by shell size, taking into account their infestation, is presented in Fig. 2.

Histological examination of the infested mollusk revealed that the tissue between the mantle and muscular layer was frayed and edematous, with a high concentration of mucin in the cell cytoplasm. In the walls of capsules consisting of a series of cells, single cercariae were found, which had a visible pigmented outer layer and underlying bundles of muscle fibers, as well as parenchyma and tubular structures located closer to the tail and representing the digestive system organs (Fig. 3). In the tissues surrounding the parasites no inflammatory reaction was observed.

Of 16 duck specimens, only the intestines of the long-tailed duck — a rarely found in the Perm Territory northern migratory marine species that winters on the shores of the Black and Azov Seas — was found to be infested with *N. attenuates* (Fig. 4). The examination revealed the thickened intestinal wall, mucous membrane of grey colour, abundantly covered with thick non-transparent mucus and grey-yellow creamy substance. Helminths were found in the mucus. Histological examination carried out with preservation of intestinal wall structure, the villi, and the crypts, revealed the dystrophic changes in the epithelial cells. Dystrophic processes were also observed in the intermuscular ganglia. A moderate macrophage response was observed in the medulla of the lymph nodes. The pronounced edematization of submucosa was observed (Fig. 5). The above changes describe the chronic toxic effect of *N. attenuates* at the place of its localization.

² According to the Data of the Ministry of Natural Resources and Environment of the Russian Federation (Perm Territory). <https://priroda.permkrai.ru/deyatelnost/okhotnichi-turizm/okhotnichi-resursy-i-okhotnichiturizm> (accessed: 5.11.2025)

Material for parasitological examination and the locations of its collection

No.	Species	Habitat	Number of specimens, pcs.
Mollusks			
Viviparidae			
1	Common river snail <i>Viviparus viviparus</i>	Kama Reservoir (Perm; Berezniki Municipality; Dobryansky District)	14
		Sylva River (Kungur District)	16
		Chusovaya River (Perm)	10
		Suzdalka River (Krasnokamsk)	1
		Mulyanka River (Perm)	1
		Lipogorsky pond (Perm)	9
Lymnaeidae			
2	Oval pond snail <i>Lymnaea ovata</i>	Usva River (Gubakhinsky District)	51
		Poludenka River (Gornozavodsky District)	3
		Koiva River (Gornozavodsky District)	1
		Kopanets River (Osinsky District)	19
		Sherya River (Nytvinsky District)	2
		Syuzva River (Krasnokamsk District)	4
		Mulyanka River (Perm)	2
		Sylva River (Kishertsky District)	1
		Maysky Pond (Krasnokamsk District)	2
		Lipogorsky pond (Perm)	4
3	Fragile pond snail <i>Lymnaea fragilis</i>	Maysky Pond (Krasnokamsk District)	13
		Koiva River (Gornozavodsky District)	5
		Sherya River (Nytvinsky District)	3
		Sylva River (Kungur District)	2
4	Great pond snail <i>Lymnaea stagnalis</i>	Suzdalka River (Krasnokamsk)	3
		Reservoirs (Krasnokamsky District: settlements Konets-Bor, Busyryata, Khukhryata, Abakshata, and Horticultural Non-Profit Partnership Syuzva-5)	65
		Kopanets River (Osinsky District)	5
		Sylva River (Perm District)	3
		Reservoir (Perm District, Horticultural Non-Profit Partnership Rodnik)	1
5	Wandering pond snail <i>Lymnaea peregra</i>	Cut-off Lake (Krasnokamsk District)	15
6	Marsh pond snail <i>Stagnicola palustris</i>	Suzdalka River (Krasnokamsk)	4
		Cut-off Lake (Krasnokamsk District)	16
7	<i>Stagnicola callomphala</i>	Syuzva River (Krasnokamsk District)	6
		Lasva River (Krasnokamsk Region)	3
8	Ear pond snail <i>Radix auricularia</i>	Suzdalka River (Krasnokamsk)	3
		Syuzva River (Krasnokamsk District)	3
		Poludenka River (Gornozavodsky District)	2
Planorbidae			
9	Whirlpool ramshorn snail <i>Anisus vortex</i>	Motovilikha Pond (Perm)	15
10	Great ramshorn snail <i>Planorbarius corneus</i>	Sherya River (Nytvinsky District)	2
		Lipogorsky Pond (Perm)	2
11	Margined ramshorn snail <i>Planorbis planorbis</i>	Kopanets River (Osinsky District)	2
		Motovilikha Pond (Perm)	5
12	<i>Planorbidae spp.</i>	Cut-off Lakes (Krasnokamsk District)	19
		Kama Reservoir (Perm)	3
Birds			
13	Mallard <i>Anas platyrhynchos</i>	Perm; Perm District; Chusovskoy District	6
14	Tufted duck <i>Aythya fuligula</i>	Perm Territory	4
15	Garganey <i>Spatula querquedula</i>	Krasnokamsk District.	2
16	Eurasian teal <i>Anas crecca</i>	Perm Territory	1
17	Long-tailed duck <i>Clangula hyemalis</i>	Mys Settlement (Chusovskoy District)	1
18	Common merganser <i>Mergus merganser</i>	Mys Settlement (Chusovskoy District)	2



Fig. 1. Cercaria of *Notocotylus sp.* found in *Anisus vortex*. Magnification $\times 400$.

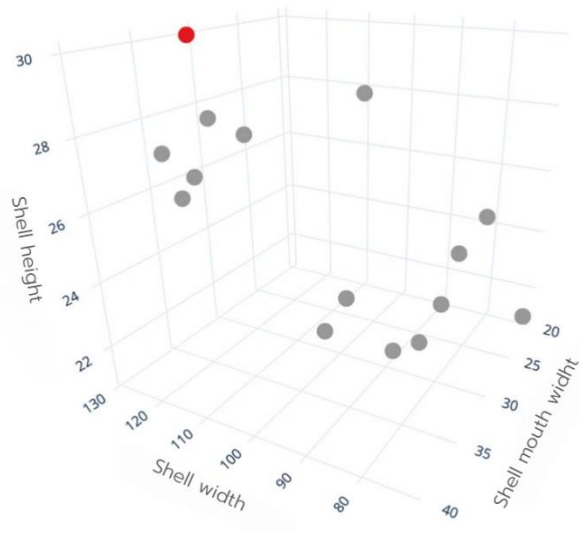


Fig. 2. Distribution of *Anisus vortex* by size, taking into account infestation (gray dots – not infested, red — infested)

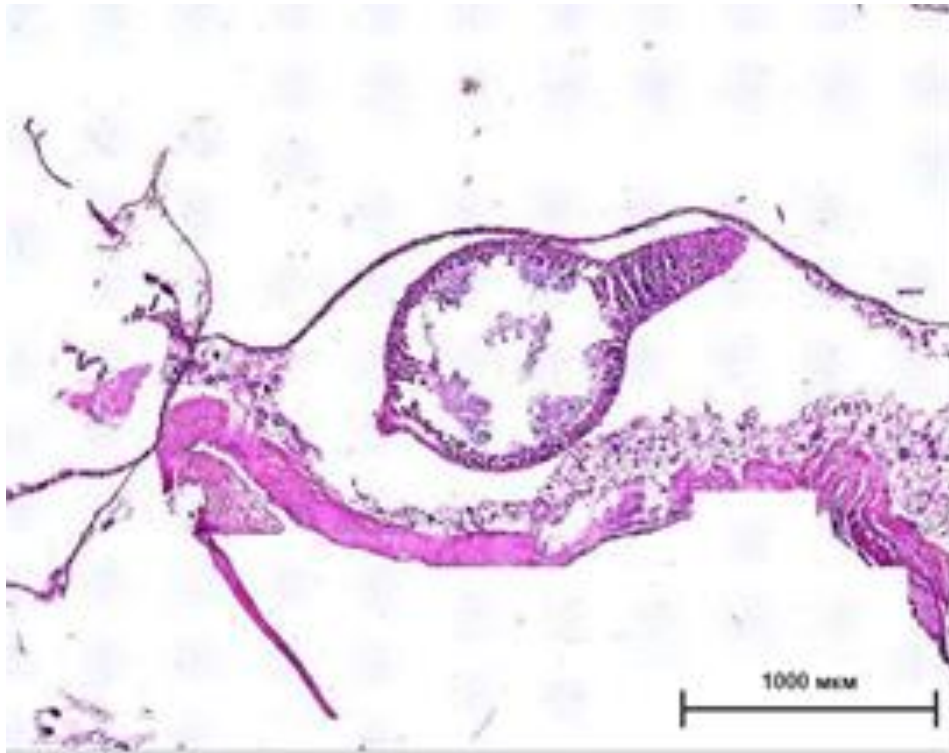


Fig. 3. *Anisus vortex* tissues infested with cercariae of *Notocotylus sp.* Magnification $\times 100$



Fig. 4. Marita of *N. attenuatus* found in the intestines of a long-tailed duck.
Magnification $\times 100$

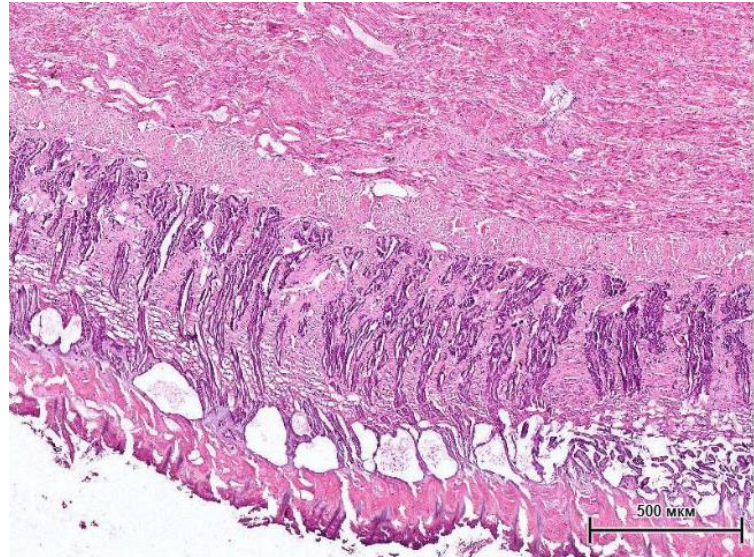


Fig. 5. Long-tailed duck intestines infested with *N. attenuatus*.
Magnification $\times 200$

Thus, the examination of freshwater mollusks in the Perm Territory resulted in acknowledging the presence of parthenites of notocotylids only in the Motovilikha Pond. Whereas, the examination of faeces of ducks from this location, had revealed no eggs characteristic for *N. attenuatus* in any of the cases, even though the concentration of mallards in this pond was significant, and the number of droppings samples examined at different time of the year equalled 53. The discovery of *N. attenuatus* in a single migratory duck is likely to indicate its infestation in nesting or wintering areas.

Discussion and Conclusion. Analysis of shell size features, made it possible to divide the sample into two groups: one group — represented by the larger and older specimens ($n=7$), which included a specimen infested with notocotylids; the second group ($n=8$) consisted of younger and smaller specimens. No information concerning the age of mollusks susceptible to infestation by notocotylids could be found in the scientific literature; however, it is acknowledged that Bithyniidae become in maximum infested with trematodes at the age of 2–3 years, and the timeline of infestation largely depends on the ambient temperature [17, 18].

Compared to similar indicators in other regions, the IE in mollusks of the family Bithyniidae in the estuary of the Kargat River (Western Siberia) during many years of observation was only 0.62%, with notocotylids being completely absent in the sample of mollusks in some of the

years. The level of infestation with parthenites of notocotylids in mollusks of the family Lymnaeidae fluctuated between 0.1 and 0.2% [10]. In our sample, Lymnaeidae were not infested by notocotylids in any of the cases. As to Bithyniidae, they were not found in any of the locations.

According to the scientific data, mallards, garganeys, shovellers, gadwalls, common pochard, and other anseriformes are often infested by notocotylids with the Infestation Intensity (II) of up to 1118 specimens [10, 21]; infestation with notocotylids is also found in many wild species worldwide [22–24]. Notocotylids are also known to parasitize not only in waterfowl, but in some micromammals too [5]. Thus, the Palearctic species *N. noyeri* had been recorded in 38.46% of voles of the species *Microtus oeconomus* near the Makhnevskaya cave (Aleksandrovsky District, Perm Territory) [26]. It could be assumed that the cercariae found in the ramshorn snails belong to notocotylids hosted by micromammals, although according to some data, some of the notocotylids, can be hosted both by birds and rodents [27].

The Motovilikha Pond is an artificial reservoir (Figs. 6–7) having the area of 0.8–0.9 km², created in 1736–1738 to serve the needs of the Motovilikha copper smelting plant. Since 1991, it got the status of a specially protected natural area of regional importance. Currently, its banks are primarily occupied by private low-rise buildings, as well as recreational areas where micromammals apparently find suitable habitat.

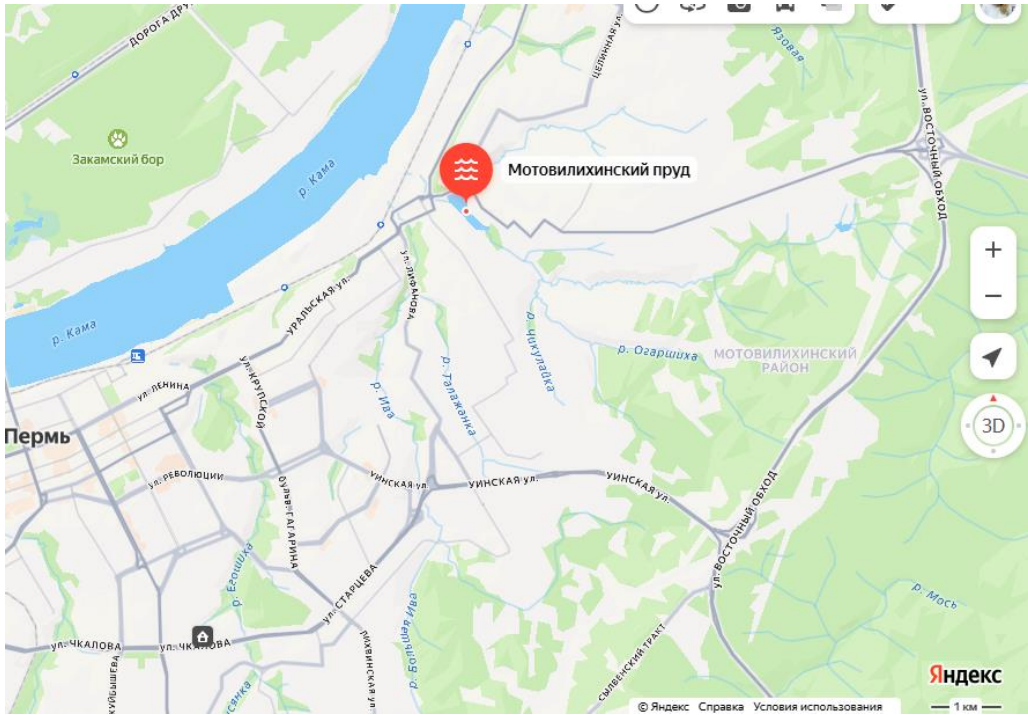


Fig. 6. Geographical location of the Motovilikha Pond in Perm



Fig. 7. Location of collecting the mollusks in the coastal area of the Motovilikha Pond

The study conducted in Perm and the Perm Territory has revealed the infestation of the mollusks of the family Planorbidae with invasive forms of notocotylids, which were not detected in the faeces of ducks from the same location. *N. attenuatus* was recorded to

parasitize only in the long-tailed duck, which is a migratory species. Therefore, a conclusion about the absence of the natural foci of notocotylidosis in birds in the studied territory can be made.

References

- Gibson DI, Jones A, Bray RA (Eds.). *Keys to the Trematoda. Volume 2*. Wallingford, UK: CABI Publishing; 2005. 768 p.
- Gonchar AG. *Life Cycles of Trematodes of the Family Notocotylidae in Ecosystems of the Northern Seas' Coasts*. Extended Abstract of Cand.Sci. (Biology) Dissertation. Saint Petersburg; 2023. 25 p. (In Russ.)
- Aguilar-Morales A, Sánchez-Nava P, Aguilar Ortigoza CJ, Rodríguez-Romero F. Variaciones Morfométricas del Género *Notocotylus* (Digenea: Notocotylidae), Parásitos de Avesacuáticas (Rallidae y Anatidae) en las Ciénegas de Lerma, Estado de México. *Acta Zoológica Mexicana*. 2022;38:1–16. <https://doi.org/10.21829/azm.2022.3812402>
- Buriro SA, Birmani NA. Morphological Study of *Notocotylus Jamshorensis* n. sp. (Trematoda: Notocotylidae) from Mallard *Anas Platyrhynchos* of Hamal Lake of Pakistan. *The Research of Medical Science Review*. 2024;2(3):2087–2093. <https://doi.org/10.5281/zenodo.14733255>
- Gagnon DK, Kasl EL, Preisser WC, Belden LK, Detwiler JT. Morphological and Molecular Characterization of *Quinqueserialis* (Digenea: Notocotylidae) Species Diversity in North America. *Parasitology*. 2021;148(9):1083–1091. <https://doi.org/10.1017/S0031182021000792>
- Flores VR, Hernández-Orts JS, Viozzi GP. A New Species of *Notocotylus* (Digenea: Notocotylidae) from the Black-Necked Swan *Cygnus Melancorhyphus* (Molina) of Argentina. *Veterinary Parasitology: Regional Studies and Reports*. 2023;45:100925. <https://doi.org/10.1016/j.vprsr.2023.100925>
- Flores V, Brugni N. *Notocotylus Biomphalariae* n. sp. (Digenea: Notocotylidae) from *Biomphalaria Peregrina* (Gastropoda: Pulmonata) in Patagonia, Argentina. *Systematic Parasitology*. 2005;61(3):207–14. <https://doi.org/10.1007/s11230-005-3166-2>
- Gonchar A, Jouet D, Skirnisson K, Krupenko D, Galaktionov K. Transatlantic Discovery of *Notocotylus Atlanticus* (Digenea: Notocotylidae) Based on Life Cycle Data. *Parasitology Research*. 2019;118:1445–1456. <https://doi.org/10.1007/s00436-019-06297-8>
- Galat VF, Yatusевич AI (Eds.) Notocotylidosis in Birds. In book: *Manual on Veterinary Parasitology*. Minsk: Information and Data Center of the Ministry of Finance; 2015. 496 p. (In Russ.) URL: <https://www.activestudy.info/nokotilidozypic/?ysclid=mh8xqzwfzg209359300> (accessed: 28.10.2025)
- Serbina EA, Bonina OM. Dynamics of Foci of Bird Notocotylidosis in the Ecosystem of Lake Chany (Western Siberia) in the Last 80 Years. *Russian Journal of Parasitology*. 2015;3:29–36. (In Russ.)
- Kodzokova EK. *Ecological and Epizootiological Assessment of Notocotylidosis in Waterfowl in the Central Caucasus Region and Development of Methods for Regulating the Number of Trematodes*: Extended Abstract of Cand.Sci. (Biology) Dissertation. Makhachkala; 2004. 25 p. (In Russ.)
- Yakovleva GA., Lebedeva D.A., Ieshko E.P. Trematodes in Wetland Birds of Karelia (Based on Materials from the 319th USSR Helminthological Expedition, 1958–1962). *Trudy Karelskogo nauchnogo tsentra RAN (Proceedings of the Karelian Research Center of the Russian Academy of Sciences)*. 2015;2:95–110. (In Russ.)
- Ovchankova NB. Taxonomic Structure and Origin of Malacofauna in River Basins of the East European Plain and the Urals. In: *Proceedings of the XI All-Russian Congress of Young Researchers in Biological Sciences with the International participation "Symbiosis—Russia 2019" (Perm, May 13–15, 2019)*. Perm: Perm State National Research University; 2019. P. 188–190. (In Russ.)
- Shepel AI, Klementyeva TN, Melnik AG. Waterfowl and Nearwater Birds of Man-Made Reservoirs and Ponds in the City Perm and Their Protection. In: *Proceedings of the All-Russian Scientific and Practical Conference Dedicated to the 25th Anniversary of the Union for the Conservation of Birds in Russia "Topical Issues in Bird Conservation" (Moscow, February 10–11, 2018)*. Moscow–Makhachkala: Union for the Conservation of Birds in Russia; 2018. P. 219–222. (In Russ.)
- Matveyeva GK, Demytyeva VV, Lapushkin VA, Kazakov VP, Kharin RV, Vasyukov SM. On the Distribution of Some Bird Species in the Perm Region. *Fauna of the Urals and Siberia*. 2024;(1):41–47. (In Russ.)
- Khokhutkin IM, Vinarsky MV. *Mollusks of the Urals and Adjacent Territories. Families Acroloxidae, Physidae, Planorbidae (Gastropoda, Pulmonata, Lymnaeiiformes). Part 2*. Ekaterinburg: Goshchitsky; 2013. 184 p. (In Russ.)
- Andreeva SI, Andreev NI, Vinarsky M.V. *Key to Freshwater Gastropods (Mollusca: Gastropoda) of Western Siberia. Part 1. Gastropoda: Pulmonata. Issue 1. Families Acroloxidae and Lymnaeidae*. Omsk; 2010. 200 p. (In Russ.)

18. Alekseev VR and Tsalolikhin SYa (Eds). *Identifier of Zooplankton and Zoobenthos of Fresh Waters of European Russia. Vol. 2. Zoobenthos*. Moscow–Saint Petersburg: Tovarishchestvo nauchnykh izdaniy KMK; 2016. 457 p. (In Russ.)
19. Cherepanov AA, Moskvina AS, Kotelnikov GA, Khrenov VM. *Atlas. Differential Diagnostics of Helminthiasis Based on the Morphological Structure of Pathogens' Eggs and Larvae*. Moscow: Rosselkhozakademiya; 2002. 85p. (In Russ.)
20. Ataeva GL, Kozminsky EV, Dobrovolskiy AA. Dynamics of Infection of Bithynia Tentaculata (Gastropoda: Prosobranchia) with Trematodes. *Parasitology*. 2002;3(36):203–218. (In Russ.)
21. Maiurova AS, Kustikova MA. Features of the First Intermediary Host Distribution of *Opisthorchis Felinus* near Major Cities of the KhMAO — Ugra (Western Siberia). *Environmental and Human Ecological Studies*. 2019;9(4):481–501. (In Russ.)
22. Vinogradova AA, Prochorova EE. Species Identification of Trematodes from Notocotylidae Family Infesting Ducks. In: Proceedings of the VIII All-Russian Conference with International Participation “School on Theoretical and Marine Parasitology” (Sevastopol, September 12–16, 2022). Sevastopol: Federal Research Center “Institute of Southern Sea Biology of the Russian Academy of Sciences named after A. O. Kovalevsky”; 2022. P. 29. (In Russ.)
23. Diaz JI, Gilardoni C, Lorenti E, Cremonte F. *Notocotylus Pprimulus* n. sp. (Trematoda: Notocotylidae) from the Crested Duck *Lophonetta Specularioides* (Aves, Anatidae) from Patagonian Coast, Southwestern Atlantic Ocean. *Parasitology International*. 2020;74:101976. <https://doi.org/10.1016/j.parint.2019.101976>
24. Mir MR, Shah GM, Jan U. Incidence and Epidemiology of *Notocotylus Attenuatus* Diesing, 1839 in Mallard Ducks (*Anas platyrhynchos*) in Various Wetlands of Pampore, Kashmir, Jkut, India. *Sustainability and Biodiversity Conservation*. 2022;1(1):84–88. <https://doi.org/10.5281/zenodo.7135072>
25. Sasaki M, Kobayashi M, Yoshino T, Asakawa M, Nakao M. *Notocotylus Ikutai* n. sp. (Digenea: Notocotylidae) from Lymnaeid Snails and Anatid Birds in Hokkaido, Japan. *Parasitology International*. 2021;83:102318. <https://doi.org/10.1016/j.parint.2021.102318>
26. Klabukov AS, Sivkova TN. Parasites in Voles at the Territory around Mahnevskaya Ice Cave (Perm Region). *Russian Journal of Parasitology*. 2020;21:133–136. (In Russ.) <https://doi.org/10.31016/978-5-9902341-5-4.2020.21.133-136>
27. Graczyk TK, Shiff CJ. Experimental Infection of Domestic Ducks and Rodents by *Notocotylus Attenuatus* (Trematoda: Notocotylidae). *Journal of Wildlife Diseases*. 1993;29(3):434–439. <https://doi.org/10.7589/0090-3558-29.3.434>

About the Authors:

Tatiana N. Sivkova, Dr.Sci. (Biology), Professor of the Department of Infectious Diseases, Perm State Agro-Technological University (23, Petropavlovskaya Str., Perm, 614990, Russian Federation), [SPIN-code](#), [ORCID](#), [Researcher ID](#), [Scopus ID](#), tatiana-sivkova@yandex.ru

Darya A. Lokteva, Postgraduate Student of the Department of Infectious Diseases, Perm State Agro-Technological University (23, Petropavlovskaya Str., Perm, 614990, Russian Federation), [SPIN-code](#), [ORCID](#), [Researcher ID](#), lokteva.dascha@yandex.ru

Margarita V. Khazova, Postgraduate Student of the Department of Infectious Diseases, Perm State Agro-Technological University (23, Petropavlovskaya Str., Perm, 614990, Russian Federation), [SPIN-code](#), [ORCID](#), margaritka92@bk.ru

Claimed Contributorship:

TN Sivkova: scientific supervision, development of the concept, coprological research, preparing the article.

DA Lokteva: research in the molluscs, preparing the article.

MV Khazova: research in birds.

Conflict of Interest Statement: the authors declare no conflict of interest.

All authors have read and approved the final manuscript.

Об авторах:

Татьяна Николаевна Сивкова, доктор биологических наук, доцент, профессор кафедры инфекционных болезней Пермского государственного аграрно-технологического университета имени академика Д.Н. Прянишникова (614990, Российская Федерация, г. Пермь, ул. Петропавловская, д. 23), [SPIN-код](#), [ORCID](#), [Researcher ID](#), [Scopus ID](#), tatiana-sivkova@yandex.ru

Локтева Дарья Александровна, аспирант кафедры инфекционных болезней Пермского аграрно-технологического университета имени академика Д.Н. Прянишникова (614990, Российская Федерация, г. Пермь, ул. Петропавловская, д. 23), [SPIN-код](#), [ORCID](#), [Researcher ID](#), lokteva.dascha@yandex.ru

Хазова Маргарита Валерьевна, аспирант кафедры инфекционных болезней Пермского аграрно-технологического университета имени академика Д.Н. Прянишникова (614990, Российская Федерация, г. Пермь, ул. Петропавловская, д. 23), [SPIN-код](#), [ORCID](#), margaritka92@bk.ru

Заявленный вклад авторов:

Т.Н. Сивкова: научное руководство, разработка концепции, копрологические исследования, подготовка статьи.

Д.А. Локтева: исследования моллюсков, подготовка статьи.

М.В. Хазова: исследование птиц.

Конфликт интересов: авторы заявляют об отсутствии конфликта интересов.

Все авторы прочитали и одобрили окончательный вариант рукописи.

Received / Поступила в редакцию 25.01.2026

Reviewed / Поступила после рецензирования 20.02.2026

Accepted / Принята к публикации 23.02.2026